

# Neoplasms of The Spine: Histologically Diagnosed Cases at a Tertiary Health Facility in North-Central Nigeria

\*Akpa PO<sup>1,2</sup>, Emmanuel I<sup>1,2</sup>, Kwaghe BV<sup>1</sup>, Alfin JD<sup>1</sup>, Shilong DJ<sup>1,4</sup>, Okwudire-Ejeh IA<sup>3</sup>, Silas OA<sup>1,2</sup>, Dauda AM<sup>1,2</sup>

<sup>1</sup> Department of Anatomic Pathology and Forensic Medicine, Jos University Teaching Hospital, Jos Plateau State, Nigeria.

<sup>2</sup> Department of Pathology, University of Jos, P.M.B 2084, Jos Plateau State Nigeria. <sup>3</sup> Division of Neurosurgery, Department of Surgery, Jos University Teaching Hospital, Jos Plateau State, Nigeria.

<sup>4</sup> Department of Surgery, University of Jos, P.M.B 2084, Jos Plateau State Nigeria. <sup>5</sup> Anatomic Pathology and Forensic Medicine Department, Asokoro district hospital, Abuja, Nigeria

## Article History

Submitted: 01/01/2024; Accepted: 09/01/2024; Published: 13/02/2024

\*Correspondence: Akpa PO.

Email: [akpaphilip@yahoo.com](mailto:akpaphilip@yahoo.com)

## ABSTRACT

Neoplasms of the spine can be primary or secondary (metastatic), they are relatively rare and occur in individuals of all ages. Their clinical manifestations include back pain, motor/sensory deficits and loss of sphincter function. These tumours can affect every region of the spine and can be intradural or extradural. This study analysed the age, sex, clinical presentation, anatomic distribution and histopathological pattern of neoplasms of the spine diagnosed histologically at the Jos University Teaching Hospital between the 1st of January 2012 and 31st December 2022. This retrospective observational study was carried out in Jos, Plateau state, North-central Nigeria. The study utilised patient hard copy case-files, electronic histopathology result records, electronic cancer registry entries and histopathology glass slides. The data obtained was analysed using Epi-info 7 (version 3.5.4) and Microsoft-Excel and presented in tables and figures. Approximately 2.4 cases of neoplasms of the spine were diagnosed per year over the 11 years of our review. Primary neoplasms were 61.5%(16) of cases and secondary neoplasms 38.5%(10). Patient ages ranged from 10 to 72 years (mean age of 42.3±16 years). There were 17 males and 9 females (M:F= 1.8:1). The commonest presenting symptoms were motor deficit (84.6%, 22) and back pain (76.9%, 20). The thoracic spine (57.7%, 15) was the commonest spinal region affected and the extradural location 53.8%(14) of cases the most frequent. In conclusion, the age and sex distribution, clinical presentation, anatomical localisation and histopathological pattern of neoplasms of the spine seen in our study is fairly consistent with published literature. We recommend improved neurosurgical and histopathological assessment and characterisation of secondary neoplasms of the spine.

**Keywords:** Extradural, Jos, Metastatic, Neoplasm, Primary, Spine, Thoracic,

## INTRODUCTION

Tumours of the spine can be primary or secondary (metastatic), primary tumours arise from the spinal cord and its surrounding appendages while secondary tumours spread from a primary site either directly to or via blood/lymphatic channels to affect the spine.<sup>1</sup>Neoplasms of the spine affect individuals of all ages, with secondary tumours

occurring in older patients in comparison to primary tumours. The higher incidence of malignancies in older individuals is largely responsible for this pattern of age distribution.<sup>2</sup>Metastatic tumours of the spine generally show a male predominance with prostate and lung cancer contributing significantly to this picture.<sup>3,4</sup>The sex distribution of primary tumours varies from place to place, a female

### Article Access



Website: [www.wjmb.org](http://www.wjmb.org)

10.5281/zenodo.14629162

### How to cite this article

\*Akpa PO, Emmanuel I, Kwaghe BV, Alfin JD, Shilong DJ, Okwudire-Ejeh IA, Silas OA, Dauda AM. Neoplasms of The Spine: Histologically Diagnosed Cases at a Tertiary Health Facility in North-Central Nigeria. *West J Med & Biomed Sci.* 2024;5(1):23-30. DOI:10.5281/zenodo.14629162.

predominance is often observed in western studies and a male predominance in Asian studies.<sup>5</sup> A male predominance of all neoplasms of the spine (primary and secondary) and a slight female predominance for primary tumours was documented in Nigeria by Chikani *et al.*<sup>6</sup>

Clinical features of neoplasms of the spine can be non-specific, with those pointing to spinal disease arising from compression of the cord or surrounding structures. The most common symptom/signs encountered in these patients are pain, motor deficit, sensory deficit and loss of sphincter function.<sup>1,6-9</sup> Other clinical features such as weight loss which do not necessarily indicate a disease of the spine may point to the nature of the underlying pathology.

A vast majority of neoplasms of the spine are secondary, it is the commonest site of musculoskeletal metastasis due to its rich venous and lymphatic interconnections.<sup>10</sup> An estimated 40% of all patients who have malignancies develop spinal metastasis in the course of their disease.<sup>11</sup> The secondary tumours that affect the spine frequently arise from the prostate, breast, lung, intestine, kidney, and thyroid.<sup>12</sup> Common primary tumours that arise from the spinal cord substance and its appendages include gliomas, meningiomas, and nerve sheath tumours.<sup>7,9,13,14</sup>

Regardless of its nature, tumours of the spine can affect all regions from the cervical down to the sacrococcygeal level. The thoracic spine is most commonly affected.<sup>2,3</sup> Tumours of the spine can be situated in the intradural or extradural location but can traverse both spaces. The intradural tumours can be intramedullary (affecting the substance of the cord) or extramedullary. A majority of metastatic tumours to the spine are extradural (95%) while two-thirds of all primary tumours of the spine are intradural-extramedullary (only 10% of primary tumours are intramedullary).<sup>15</sup>

There is no previous study on the characterisation of histologically diagnosed neoplasms of the spine in our institution. Literature search reveals that only few of such studies have been carried out in Nigeria with none identified for North-central Nigeria. This study aims to document the age and sex distribution,

presenting clinical features, anatomic distribution and histomorphological pattern of neoplasms of the spine diagnosed histologically at the Jos University Teaching Hospital (JUTH).

## MATERIALS AND METHODS

This is a retrospective observational study that reviewed all neoplasms of the spine diagnosed at the Department of Anatomic Pathology and Forensic medicine of the Jos University Teaching Hospital (JUTH) between the 1st January 2012 to 31st December 2022. JUTH is a tertiary health Institution and a referral center located in Plateau state, North-central Nigeria. Materials consisted of patient hard copy case files, electronic histopathology result records, electronic cancer registry entries, histopathology glass slides and formalin fixed paraffin embedded tissue blocks. The patient age, sex, presenting clinical features and anatomic location of tumour in the spine were recorded for all cases using the aforementioned materials. Archived glass slides and freshly made slides from tissue blocks in cases of missing or poor-quality slides were used for re-evaluation of histopathology diagnosis. The glass slides of all cases of neoplasms of the spine were reviewed by the authors of this research to confirm and record the diagnosis. The data obtained was analysed using Epi-info 7 (version 3.5.4) and Microsoft-Excel. Results were presented in tables and charts.

## RESULTS

The records of 27 cases of neoplasms of the spine were reviewed, 26 met the inclusion criteria and 1 case was excluded for incomplete information. Approximately 2.4 cases of neoplasms of the spine were diagnosed per year over the 11 years of our review. The Patient ages ranged from 10 to 72 years with a mean age of 42.3±16 years and peak of occurrence in the fourth decade (tables 1). There were 17 males and 9 females with a male to female ratio of 1.8:1. (table 2). Twenty two (84.6%) out of the 26 patients presented with motor deficit while 20 (76.9%) presented with back pain (figure 1). The thoracic spine (57.7%) was the commonest spinal region affected (figure 2) and the commonest location in relation to the dura of the spine was

extradural (53.8%,14) (figure 3) Sixteen cases (61.5%) were primary and 10(38.5%) secondary (table 2). The commonest primary tumour was meningioma which accounted for 31.2%(5) of primary tumours (table 2). The prostate which accounted for 30% of cases (3 out of 10)was the commonest secondary source of tumour spread to the spine (figure 4)

Table 1. showing age and gender distribution of patients with neoplasms of the spine

S/No	Age Interval (years)	Male (%)	Female (%)	Frequency (%)
1	0 - 10	1 (3.8)	0	1 (3.8)
2	11 - 20	1 (3.8)	0	1 (3.8)
3	21 - 30	1 (3.8)	2 (7.7)	3 (11.5)
4	31 - 40	6 (23.1)	3 (11.5)	9 (34.6)
5	41 - 50	4 (15.4)	2 (7.7)	6 (23.1)
6	51 - 60	0	1 (3.8)	1 (3.8)
7	>60	4 (15.4)	1 (3.8)	5 (19.2)
<b>Total</b>		<b>17 (65.4)</b>	<b>9 (34.6)</b>	<b>26 (100)</b>

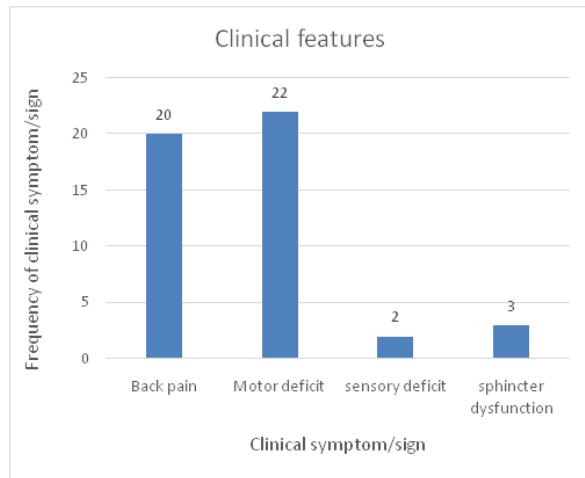


Figure 1. Chart showing distribution of Clinical features

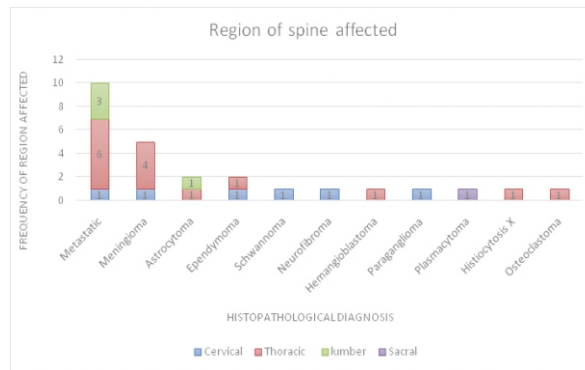


Figure 2. Chart showing the regions of the spine affected

Table 2. Table showing histopathological diagnosis and sex distribution of neoplasms of the spine

S/N	Histological diagnosis	Sex		Frequency (%)
		Male (%)	Female (%)	
1	<b>Metastasis (Secondary tumours)</b>	6 (23.1)	4 (15.4)	10 (38.5)
<b>Primary tumours</b>				
2	Meningioma (WHO grade I)	2 (7.7)	3 (11.5)	5 (19.2)
3	Diffuse fibrillary astrocytoma (WHO grade II)	2 (7.7)	0	2 (7.7)
4	Ependymoma (Tanycytic variant, WHO grade II)	2 (7.7)	0	2 (7.7)
5	Plasmacytoma	1 (3.8)	0	1 (3.8)
6	Histiocytosis X	1 (3.8)	0	1 (3.8)
7	Neurofibroma	1 (3.8)	0	1 (3.8)
8	Schwannoma	1 (3.8)	0	1 (3.8)
9	Haemangioblastoma	0	1 (3.8)	1 (3.8)
10	Paraganglioma	1 (3.8)	0	1 (3.8)
11	Osteoclastoma	0	1 (3.8)	1 (3.8)
<b>Total</b>		<b>17 (65.4)</b>	<b>9 (34.6)</b>	<b>26 (100)</b>

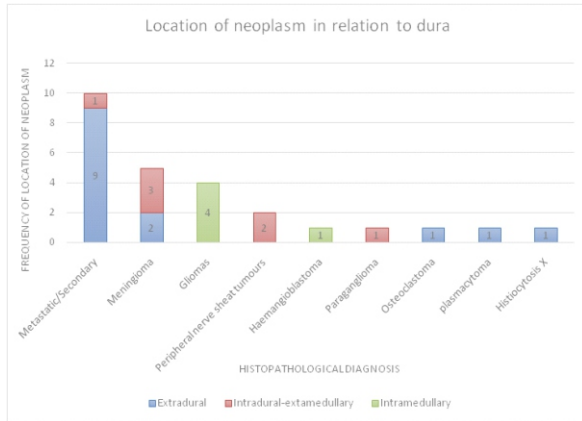


Figure 3. Chart showing the anatomic localisation of neoplasms of the spine in relation to the Dura

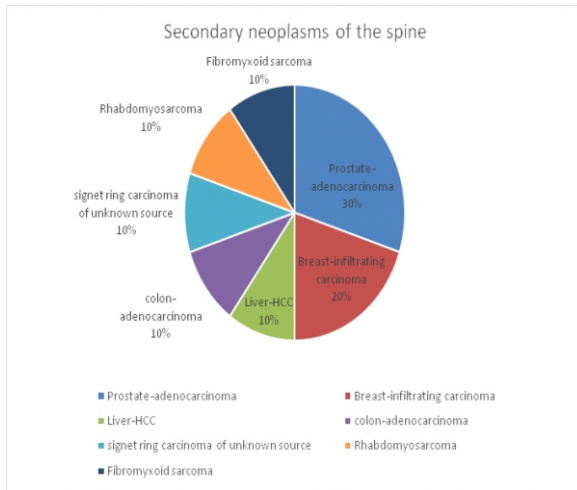


Figure 4. Pie chart showing the primary sources of secondary neoplasms of the spine

**DISCUSSION**

Neoplasms of the spine are infrequently diagnosed in our institution, approximately 2.4 cases were seen per year over the 11 years of our review. They occurred in patients between the ages of 10 to 72 years (mean age 42.3±16 years )with a peak of occurrence in the fourth decade (table 1).The mean ages of primary and secondary tumours were 34.1±10 and 55.4±15years respectively. The mean age of those with secondary tumours was two decades older. This closely mimics the report by Chikani *et al*, in South-eastern Nigeria whereby patients who had secondary spinal neoplasms were older by one decade.<sup>6</sup>The higher mean age of secondary neoplasms are attributable to the increased incidence of malignancies such as prostate and breast cancer in older patients. These are the

commonest causes of spinal metastasis in our study and others studies alike.<sup>2</sup>

Our study revealed a male predominance with a male to female ratio of 1.8:1, this male predominance was even greater when only primary spinal neoplasms are considered (M:F=2.2:1) (Table 2). This correlates with the findings of Chikani *et al*, in South-eastern Nigeria (M:F=1.8:1) and Arora *et al*, in India (M:F=2.5:1) who both documented a male predominance.<sup>6,13</sup>This however contrasts with the report by Adeolu *et al*, (South-Western Nigeria)who documented a slight female predominance(M:F=1:1.1).<sup>16</sup>

The non-specificity of the symptoms and signs of spinal neoplasms can often lead to misdiagnosis.<sup>17,18</sup>The commonest clinical features are pain and motor/sensory dysfunction.<sup>7,13,19</sup>Back pain, neck pain and radicular pain are the forms of pain frequently seen.<sup>20</sup>Numbness, loss of proprioception, limb weakness, limb paralysis, and loss of bowel/bladder control are the forms of sensory and motor dysfunction encountered.<sup>6,13,19,20</sup> A majority of our patients presented with motor deficit (84.6%)and back pain (76.9%), with fewer patients presenting with urinary incontinence (11.5%) and sensory deficits (7.7%) (figure 1). The pattern of clinical presentation seen in our study is consistent with the report of other authors.<sup>6,13,21</sup>

In an ideal setting where most tumours of the spine are assessed and characterized, greater than 90% are secondary.<sup>10</sup>Our study revealed a predominance of primary tumours (61.5%) over secondary tumours (38.5%) (table 2). The predominance of primary tumours over secondary tumours in our study is attributable to the fact that, in a resource poor setting like ours, a large number of our patients who have secondary spinal neoplasms neither have surgery or biopsy for histology. Generally only about 10% of secondary tumours of the spine are amenable to surgery.<sup>1</sup>A majority of surgical interventions are for palliation to relieve associated neurological deficit, intractable pain or to correct instability of the spine.<sup>22,23</sup>

The thoracic spine was the most commonly affected region of the spine accounting for 57.7% of cases

followed by the cervical spine (23.1%) (figure 2). This is in keeping with reports of other authors in Nigeria and elsewhere.<sup>6,13,14,16,21</sup> The predilection of the thoracic spine to common lesions such as metastasis and meningioma contributes a large part to this finding in our study and other studies alike.<sup>6,13</sup> Fifty three percent (53.8%) of all cases in our study were extradural, the next most common location being intradural-extramedullary (26.9%). The intramedullary tumours were the least common at 19.2% (figure 3). A majority (9 out of 14) of the extradural tumours in our study were metastatic. Most metastatic tumours are extradural (95% of cases) which includes both purely epidural tumours and tumours of vertebral bodies extending into the epidural space.<sup>3,24</sup> A majority of meningiomas and all cases of peripheral nerve sheath tumour were intradural-extramedullary. The intramedullary tumours consisted of all cases of glioma and a case of hemangioblastoma (figure 3). The anatomical distribution of the histological entities diagnosed in our study is consistent with reports by other authors in both Nigerian and international studies.<sup>6,7,13,21</sup>

Primary spinal cord neoplasms are histologically similar to their intracranial counterpart, but they are ten times less common and a majority are benign<sup>1,13,25-27</sup> This is reflected in our study whereby 93.7% of primary neoplasms were benign. The commonest primary neoplasms of the spine were meningioma, gliomas (astrocytoma/ependymoma) and nerve sheath tumours.

Our five cases of spinal meningioma accounted for 19.2% all spinal neoplasms and 31.2% of primary (non-metastatic) tumours, all cases were WHO grade I tumours. This is in keeping with published literature which shows that spinal meningiomas account for between 15-46% of primary neoplasms of the spine and a majority are WHO grade I tumours.<sup>14,28-30</sup> All except one of our spinal meningiomas occurred in the 4<sup>th</sup> decade (mean age of 38.6±6 years), which is significantly younger than the peak of diagnosis in the 6<sup>th</sup> and 8<sup>th</sup> decades seen worldwide.<sup>8,28</sup> This is most likely attributable to our younger population. Neurofibromatosis 2 (NF2) is associated with an increased risk of and occurrence of spinal meningiomas in young people.<sup>28,29</sup> None of

our patients were tested for NF2. Our study showed a slight female gender bias of meningioma (M:F=1:1.5) (table 2), which correlates with a female gender predominance of spinal meningioma diagnosis commonly seen.<sup>7,8,13,14,28</sup> Female gender and radiation exposure are established risk factors for meningioma.<sup>31</sup> Three of our meningioma cases were intradural-extramedullary and two cases extradural (figure 3). Extradural meningiomas are rare, they account for between 2.5-3.5% of spinal meningiomas and are commonly mistaken for metastatic tumours.<sup>32,29</sup> The relatively high percentage contribution of extradural meningiomas in our study is most likely coincidental. A majority of meningiomas (about 80%) arise in the thoracic spine<sup>14,33</sup> this correlates with our findings in which four out of five cases (80%) occurred in the thoracic region

Only two cases of peripheral nerve sheath tumours of the spine were diagnosed during the period of our review. A case of Neurofibroma in a 10-year-old male and a case Schwannoma in a 23-year-old male. Both cases were intradural-extramedullary and localised at the cervical spine. Spinal nerve sheath tumours are the most frequent intradural-extramedullary primary neoplasms of the spine ahead of meningioma in a significant number of reports.<sup>8,13,14</sup> The frequency of nerve sheath tumours is higher than meningiomas in Asian studies while the reverse is seen in western studies, our findings align with the latter which is also supported by the Surveillance, Epidemiology, and End Results (SEER) database.<sup>9,34</sup> They do not show a gender predilection and are most commonly seen in the cervical and lumbar regions.<sup>8</sup> Even though most nerve sheath tumours are intradural, about 25% are completely extradural while 15% extend from the intradural to extradural space.<sup>8</sup> The peak period of occurrence is in the 4<sup>th</sup> decade and 90% of cases are benign.<sup>8</sup> Both of our cases were benign but however occurred in young patients.

Gliomas are the commonest intramedullary spinal cord tumours accounting for about 80% of cases.<sup>35</sup> Astrocytomas and ependymomas are the most common of these gliomas.<sup>13,19,25,35</sup> There were 5 cases of intramedullary spinal cord tumours diagnosed

during the period of our review, accounting for about 19.2% of all cases of spinal neoplasm. This is a relatively high percentage compared to the about 5% of primary spinal tumours documented in literature.<sup>36</sup> Astrocytomas have a higher frequency of occurrence in children than in adults while the reverse is true for ependymomas<sup>13,25,35</sup> All cases of astrocytoma (mean age 40.5±2 years) and ependymoma (mean age 40±7 years) occurred in adults in our study. Ependymomas are the commonest intramedullary spinal cord neoplasms accounting for about 60% of the spinal glial tumours, while astrocytomas come second.<sup>20,37</sup> Our study however had an equal frequency of occurrence of both. Most ependymomas are slow growing WHO grade II tumours and spinal astrocytomas tend to be of lower grade than those diagnosed in the intracranial cavity (75% of cases being of grade I and II).<sup>20</sup> The grade of gliomas in our study is consistent with these. Spinal astrocytomas have a worse prognosis than spinal ependymomas due to their faster growth and tendency for incomplete resection<sup>20</sup>

As stated earlier, secondary neoplasms of the spine arise from a wide variety of primary sites, 30% of cases in our study were of prostatic origin while 20% were from the breast. The Breast and prostate are consistently the commonest primary sites of metastatic tumours to the spine.<sup>2</sup> Six of the spinal secondaries occurred in the thoracic region, three cases affected the lumbar region and one occurred in the cervical spine. The tendency of metastasis to the thoracic spine is due to its proximity to nearby organs, its rich vascular supply and its greater number of vertebrae compared to other spinal regions.<sup>2,3</sup> Nine of the ten secondary spinal neoplasms in our study were extradural and one case intradural-extramedullary, this is also consistent with published literature.<sup>1,3,6</sup>

## CONCLUSION

The age distribution, sex distribution and presenting clinical features of patients with spinal neoplasms in our institution is fairly consistent with available published literature. The anatomical distribution of the different histopathological types of neoplasms of the spine is also consistent. The predominance of

primary neoplasms over secondary neoplasms in our study is a reversal of the norm but attributable to peculiarities of practice in our environment whereby a majority of secondary neoplasms are not biopsied for histology.

## Recommendation

It is recommended that more effort is made in the assessment and characterisation of secondary tumours of the spine in our environment. This effort should entail radiological investigations in patients with advanced malignancies to identify spinal metastasis for possible histopathological analysis.

## Acknowledgment

We wish to acknowledge the kind assistance of the staff of the cancer registry and records department of the Jos University Teaching Hospital.

## Conflict(s) of Interest

Authors declare there are no conflicts of interest

## REFERENCES

1. Ciftdemir M, Kaya M, Selcuk E, Yalniz E. Tumors of the spine. *World J Orthop.* 2016;7(2): 109-116.
2. Shah LM, Salzman KL. Imaging of Spinal Metastatic Disease. *Int J Surg Oncol.* 2011;2011:769753.
3. Elmesallamy WAA, Taha MM. Surgical management and prognostic factors of spinal metastatic tumours. *Egyptian Journal of Neurosurgery.* 2020; 35(1): 1-8. (<https://doi.org/10.1186/s41984-020-00080-z>)
4. Sciubba DM, Petteys RJ, Dekutoski MB, Fisher CG, Fehlings M, Ondra SL, Rhines LD, Gokaslan ZL. Diagnosis and management of metastatic spine disease: a review. *J Neurosurg Spine.* 2010;13(1):94-108.
5. Hirano K, Imagama S, Sato K, Kato F, Yukawa Y, Yoshihara H, *et al.* Primary spinal cord tumors: Review of 678 surgically treated patients in Japan. A multicenter study. *Eur Spine J.* 2012;21:2019-26.
6. Chikani MC, Messi M, Okwunodulu O, Mezue W, Ohaegbulam S, Ndubuisi C, *et al.* Pattern of

- presentation and surgical management of spine tumors in Southeast Nigeria over a 10-year period. *Niger J Clin Pract.* 2020;23(8):1167-71.
7. Chikani MC, Okwunodulu O, Mesi M, Mezue WC, Ohaegbulam SC, Ndubuisi CC. Surgically treated primary spinal cord neoplasms in Southeastern Nigeria. *J Neurosci Rural Pract.* 2018;9(1):137-9.
  8. Arnautovic K, Arnautovic A. Extramedullary intradural spinal tumours: A review of modern diagnostic and treatment options and a report of a series. *Bosnian Journal of basic medical sciences* 2009;9(1): S40-S45
  9. Wu Y, Chang C, Hsu S, Yip C, Liao W, Chen J *et al.* Intraspinal tumors: Analysis of 184 patients treated surgically. *Journal of the Chinese Medical Association.* 2014;77(12): 626-9
  10. Lewandrowski KU, Anderson ME, McLain RF. Tumors of the Spine. In: Herkowitz HN, Garfin SR, Eismont FJ, Bell GR, Balderston RA. Philadelphia: Elsevier Saunders, 2011: 1480-1512
  11. Klimo P Jr, Schmidt MH. Surgical management of spinal metastases. *Oncologist.* 2004;9(2):188-96.
  12. Choi D, Crockard A, Bungler C, Harms J, Kawahara N, Mazel C, Melcher R, Tomita K. Review of metastatic spine tumour classification and indications for surgery: the consensus statement of the Global Spine Tumour Study Group. *Eur Spine J.* 2010; 19: 215-222
  13. Arora RK, Kumar R. Spinal tumors: Trends from Northern India. *Asian J Neurosurg.* 2015;10(4):291-7.
  14. Koeller KK, Shih RY. Intradural Extramedullary Spinal Neoplasms: Radiologic-Pathologic Correlation. *RadioGraphics.* 2019; 39(2):468–90. doi.org/10.1148/rg.2019180200.
  15. Chamberlain MC, Tredway TL. Adult primary intradural spinal cord tumors: A review. *Curr Neurol Neurosci Rep.* 2011;11:320-8.
  16. Adeolu AA, Oyemolade TA, Salami AA, Adigun TA, Malomo AO, Akang EA *et al.* Features and Outcome of Surgical Management of Spinal Tumors in a Cohort of Nigerian Patients. *World Neurosurgery.* 2015 ;84(4):1090-4
  17. Granado AQ, Roselló EG, Sala GL, García R, Caro JL, Pérez F, *et al.* A Comprehensive Review of Intraspinal Tumors: Diagnostic, Classification and Radio-Pathologic Correlation. *European Congress of Radiology- E C R 2 0 1 3 .* Available from : <http://www.myESR.org>. [Last accessed on 2023 Dec 16].
  18. Govind M, Radheysyam M, Achal S, Ashok G. Intradural extramedullary spinal cord tumors : A retrospective study at tertiary referral hospital. *Rom Neurosurg* 2016;XXX: 106-12.
  19. Kretzer RM. Intradural Spinal Cord Tumors. *S p i n e .* 2 0 1 7 ; 4 2 : S 2 2 . doi : 10.1097/brs.0000000000002032.
  20. Wein S, Gaillard F. Intradural spinal tumours and their mimics: a review of radiographic features. *Postgrad Med J .* 2 0 1 3 ; 8 9 ( 1 0 5 4 ) : 4 5 7 – 6 9 . doi:10.1136/postgradmedj-2012-131503
  21. Tilva KK, Parikh U. Histopathological Spectrum of Spinal Tumours at a Tertiary Care Hospital, Gujarat, India: A Retrospective Study. *Journal of Clinical and Diagnostic Research.* 2023;17(1)
  22. Wise JJ, Fischgrund JS, Herkowitz HN, Montgomery D, Kurz LT. Complication, survival rates and risk factors of surgery for metastatic disease of the spine. *Spine.* 1999;24(18):1943–51.
  23. Nathan SS, Healey JH, Mellano D, Hoang B, Lewis I, Morris CD, et al. Survival in patients operated on for pathologic fracture: implications for end-of-life orthopedic care. *J Clin Oncol.* 2005;23(25):6072-82.
  24. Rose PS, Buchowski JM. Metastatic Disease in the Thoracic and Lumbar Spine: Evaluation and Management. *J Am Acad Orthop Surg.* 2011; 19(1): 37-48.
  25. Samartzis D, Gillis CC, Shih P, O'toole JE, Fessler RG. Intramedullary Spinal Cord Tumors: Part I—Epidemiology,

- Pathophysiology, and Diagnosis. *Global Spine J*. 2015;5:425–35
26. Ravi N, Manjappa BH, Nagaraj BR, Naveen KG, Lakshmeesha MT, Ramesh V, *et al*. MRI evaluation of different spectrum of spinal tumors. *SSRG Int J Med Sci*. 2014;1:14-30.
  27. Özkan N, Jabbarli R, Wrede KH, Sariaslan Z, Stein KP, Dammann P, *et al*. Surgical management of intradural spinal cord tumors in children and young adults: a single-center experience with 50 patients. *Surg Neurol Int*. 2015;6(suppl 27):S661–S667
  28. Maiti TK, Bir SC, Patra DP, Kalekoti P, Guthikonda B, Nanda A. Spinal Meningiomas: Clinicoradiological factors predicting recurrence and functional outcome. *Neurosurg Focus*. 2016;41(2):E6.
  29. Sandalcioglu IE, Hunold A, Muller O, Bassiouni H, Stolke D, Asgari S. Spinal meningiomas: critical review of 131 surgically treated patients. *Eur Spine J*. 2008; 17:1035–1041. doi 10.1007/s00586-008-0685-y
  30. Kwee LE, Harhangi BS, Ponne GA, Kros JM, Dirven CM, Dammers R. Spinal meningiomas: Treatment outcome and long-term follow-up. *Clinical Neurology and Neurosurgery*. 2020;198:106238.
  31. Perry A, Louis DN, Budka H, *et al*. Meningioma. In: Louis DN, Ohgaki H, Wiestler OD, *et al*, eds. WHO classification of tumours of the central nervous system. Revised 4th ed. Lyon, France: IARC, 2016; 232–237.
  32. Dehcordi SR, Ricci A, Chiominto A, De Paulis D, Di Vitantonio H, Galzio RJ. Dorsal extradural meningioma: Case report and literature review. *Surg Neurol Int*. 2016;7:76.
  33. Voldrich R, Netuka D, Benes V, Spinal meningiomas: is Simpson grade II resection radical enough?. *Acta Neurochirurgica*. 2020;162:1401-8. doi.org/ 10.1007/s00701-020-04280-2.
  34. Westwick HJ, Shamji MF. Effects of sex on the incidence and prognosis of spinal meningiomas: a Surveillance, Epidemiology, and End Results study. *J Neurosurg Spine*. 2015;23(3):368–373.
  35. Viridi G. Intramedullary Spinal Cord Tumours: A Review of Current Insights and Future Strategies. *Spine Res*. 2017;3(2):13. doi: 10.21767/2471-8173.100013.
  36. Greenberg MS. *Handbook of Neurosurgery*. 8th ed. New York: Thieme; 2016. p. 783-99.
  37. Manzano G, Green BA, Vanni S, Levi AD. Contemporary management of adult intramedullary spinal tumors – pathology and neurological outcomes related to surgical resection. *Spinal Cord*. 2008;46(8):540–6.