

Original Article

# Metastatic Ocular Melanoma to the Breast and Axillary Lymph Nodes: An Unusual Case Presentation.

Omenai SA<sup>1\*</sup>, Agbonrofo PI<sup>2\*</sup>

<sup>1</sup> Department of Anatomical Pathology, Edo State University Uzairue, Edo State, Nigeria

<sup>2</sup> Department of Surgery, University of Benin, Edo State, Nigeria

## Article History

Submitted: 20/12/2023; Accepted: 19/01/2024; Published: 17/02/2024

\*Correspondence: Sebastian A. Omenai

Email: [sebeanom@gmail.com](mailto:sebeanom@gmail.com)

## ABSTRACT

Melanoma including ocular melanoma commonly metastasizes to the liver, lungs and pleurae. Melanoma can have an indolent growth and can also be a challenge to diagnose during morphological evaluation. Rarely, it can metastasize to the breast. This 57-year-old woman presented with a breast lump and axillary lymphadenopathy of 4 months duration. A diagnosis of poorly differentiated breast carcinoma on biopsy was made. Subsequent mastectomy done showed pigmented malignant melanocytes within the breast and axillary lymph nodes. The laboratory then obtained previous ocular oncology history, and a diagnosis of metastatic melanoma to the breast and axillary lymph nodes was made. Clinicians and pathologists should therefore suspect a metastatic neoplasm in the breast in a patient with an ocular melanoma history.

**Keywords:** Breast cancer; mastectomy; metastatic melanoma; ocular melanoma.

## INTRODUCTION

Ocular melanoma is the most common primary intraocular malignancy in adults<sup>1</sup>. Uveal melanoma is the most common type with the choroid being the most frequent site of origin compared to the ciliary body<sup>1</sup>. Other ocular melanomas include those arising from the iris and conjunctival. Iris melanoma is the least common and commonly affects younger age group, while conjunctival melanoma mostly affects Caucasians<sup>1</sup>. In general, ocular melanoma is not very common in our environment, in a study by Akpe et al in Benin-City, Nigeria, ocular melanoma was 9.1% of enucleated specimens while in a study conducted in Zaria by Mohammed et al. melanoma was 2.6% of orbito-ocular malignancies<sup>2,3</sup>.

Metastatic dissemination of ocular melanoma occurs predominantly in the liver, lungs, and bones<sup>1</sup>. Breast metastasis from ocular melanoma is extremely rare, with a few cases reported in the literature<sup>4-6</sup>. Metastatic tumours to the breast are rare<sup>7,8</sup>. Melanoma can be primary in the breast skin and secondarily involve the breast tissue. Very rare primary cases arising from the glandular tissue of the breast also occur<sup>9,10</sup>.

Majority of secondary melanomas in the breast are from cutaneous melanomas primarily<sup>10-12</sup>. Arora et al in their review of malignant melanoma metastatic to the breast showed that the median interval between initial diagnosis of primary melanoma and breast involvement was 33 months with a range of 2-132months<sup>13</sup>.

## Article Access



Website: [www.wjmb.com.org](http://www.wjmb.com.org)  
DOI: 10.5281/zenodo.7481754

## How to cite this article

\*Omenai SA, Agbonrofo PI. Metastatic Ocular Melanoma to the Breast and Axillary Lymph Nodes: An Unusual Case Presentation. *West J Med & Biomed Sci.* 2024;5(1)19-22. DOI:10.5281/zenodo.7481754

Here, we describe a unique case of ocular melanoma metastasizing to the breast and axillary lymph nodes and associated literature review

## CASE REPORT

A 57-year-old female presented with a painless, palpable lump in the upper outer quadrant of her right breast with matted enlarged right axillary lymphadenopathy. The patient had a known history of ocular melanoma, treated with enucleation of the left eye three years ago. She had not been regular with her follow-up and surveillance clinics. She had the past oncology history in a different hospital before presenting in our facility. She had no history of tumour recurrence or metastases before the current presentation.

Physical examination revealed a firm, mobile mass measuring approximately 4cm in diameter in the right breast. No nipple changes, or skin abnormalities. There were multiple axillary lymphadenopathies noted in the ipsilateral axilla.

### Diagnostic Workup

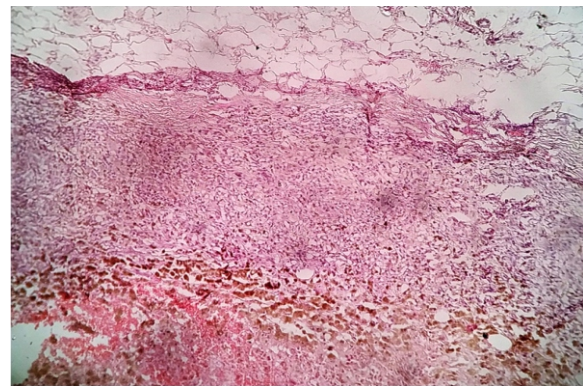
A biopsy of the breast mass was performed, and initial histological examination revealed the presence of poorly differentiated malignant cells with areas of hemorrhage. Initial diagnosis of primary breast carcinoma was obtained. The laboratory was unaware of the oncological history of the patient at that time. Chest x-ray revealed evidence of lung metastases. She then had right mastectomy and axillary lymph node dissection. Histological evaluation showed residual pigmented malignant melanocytes in the breast with involvement of 5 of the recovered lymph nodes, the sections showed complete effacement of 3 of the nodes by heavily pigmented spindle to epithelioid cells (Fig 1 and 2). The overlying breast skin was normal. The previous oncological history of ocular melanoma was then obtained by the laboratory after contact with the surgeon and a diagnosis of metastatic melanoma to the breast and axillary lymph nodes was made.

The liver, skin, and bones were normal on further evaluation.

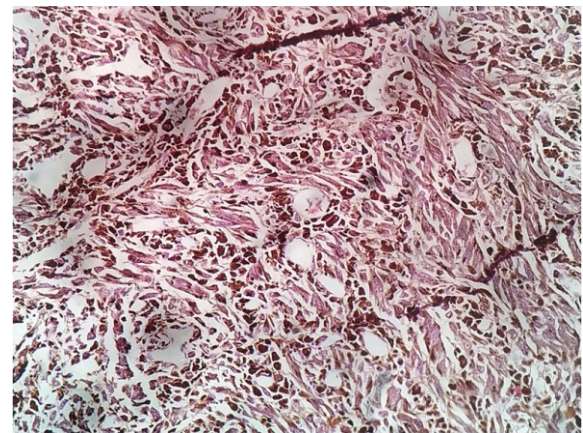
### Treatment and Outcome

Postoperatively, the patient received adjuvant cytotoxic chemotherapy. However, there was poor response to treatment and patient subsequently died from disease progression 3 months post-operatively.

Consent was obtained from patient, prior to demise, to share the photomicrographs and other data which are presented in this report. A waiver from the institutional ethics committee was secured for this report.



**Figure 1.** Breast mass showing pleomorphic and pigmented melanocytic cells. The malignant cells infiltrate adipose tissue, with areas of hemorrhage (H&E x40).



**Figure 2:** The photomicrograph shows a lymph node completely effaced and replaced by malignant spindle to epithelioid cells with melanocytic pigmentation (H&E x100).

## DISCUSSION

Metastatic ocular melanoma to the breast is an exceedingly rare occurrence<sup>5,7</sup>. The breast can be a site of metastases in patients with malignant melanoma such as our index case. This metastatic mammary tumour can be challenging to diagnose and the tendency to diagnose a primary breast cancer can happen such as in this index case<sup>11,14</sup>. The most

important source of melanoma metastases to the breast is from cutaneous melanoma<sup>9,10</sup>.

Ocular melanoma is the most common intraocular tumour in adults<sup>1</sup>. An ocular melanoma can arise from the choroid and ciliary body which is commonly referred to as uveal melanoma or from the Iris<sup>1</sup>. Uveal melanomas are common between the 6<sup>th</sup> and 8<sup>th</sup> decade of life while Iris melanoma tends to occur in the younger age category<sup>1</sup>. Taran-Munteanu reported a case of a 61-year old woman who had choroidal melanoma that metastasized to the left breast after a 50 months interval<sup>4</sup>. This is similar to our case who is a 57-year-old woman that had a diagnosis and treatment for ocular melanoma about 24 months before presenting in our facility with breast lump. Demirci et al. also reported a case of a 48 year old woman with choroidal melanoma that was metastatic to both breasts after a 37 months interval<sup>5</sup>. In a review of about 27 cases of cutaneous metastatic melanoma to the breast, 70% of cases were postmenopausal and 82.6% of the cases had primary lesions in the upper part of the body<sup>12</sup>.

Metastatic malignant melanoma to the breast can be investigated and diagnosed by core cut, FNAC with or without mammogram<sup>15,16</sup>. Just like in our present case, Vinyuvat reported a case that mimicked an initial diagnosis of primary breast carcinoma on core biopsies<sup>14</sup>. The patient, similar to our index case, had radical mastectomy that revealed the malignant melanocytes and after contact with the surgeons with additional clinical information a diagnosis of melanoma was made but unlike in our case the axillary lymph nodes were not involved<sup>14</sup>. Barnett et al, in line with our index case, also reported a rare case of metastatic melanoma from a cutaneous primary lesion that involved the right breast and axillary lymph nodes<sup>8</sup>. Melanoma, when not pigmented, can be a challenging diagnosis and is commonly referred to as the great mimicker; thus a missing or incomplete history of a primary melanoma can lead to misdiagnosis<sup>11,12</sup>. Bacchi et al. reported that only 10% of metastatic melanomas are heavily pigmented<sup>11</sup>. In such difficult and challenging situations, immunohistochemistry can be of help<sup>11</sup>.

Metastatic melanoma to the breast can be managed

surgically by either conservative breast preserving surgery or mastectomy<sup>4,13,14,16</sup>. This case was managed with a modified radical mastectomy as was the case of Vinyuvat<sup>14</sup>. The median survival following metastatic melanoma in a review by Ravel et al is 12.9months<sup>12</sup>. The optimal treatment strategy for such cases remains uncertain due to the limited evidence available. A multidisciplinary approach is essential to guide individualized treatment plans and achieve the best possible outcomes

Clinicians should consider the possibility of metastases in patients with a history of ocular melanoma who present with breast masses and also provide this critical information to the pathologist. Core needle biopsies can also be used for accurate diagnosis, as clinical and radiological features may overlap with primary breast malignancies<sup>16</sup>.

## CONCLUSION

This case highlights the importance of recognizing unusual metastatic patterns and considering metastatic ocular melanoma in the differential diagnosis of breast masses in patients with a history of ocular melanoma. Further research and case reports are warranted to better understand the management and prognosis of such rare cases.

## Recommendations

Multidisciplinary collaboration between oncologists, dermatologists, radiologists, and pathologists can improve diagnostic accuracy through comprehensive evaluation and shared decision-making. Hospitals should implement clear guidelines for managing oncology patients with ambiguous presentations as this can expedite accurate diagnosis and reduce delays in treatment.

**Ethical Issues:** Written consent was obtained from the patient prior to demise to share photomicrograph and data while adhering strictly to the Helsinki declaration of maintaining confidentiality and dignity of patients.

**Conflict of Interests:** The authors declare no conflict of interest.

**Author contribution:** Both authors were involved in the management of the patient and, S.A.O conceptualized the case report. Both authors wrote

and approved the final manuscript.

## REFERENCES

1. Jovanovic P, Mihajlovic M, Djordjevic-Jocic J, Vlajkovic S, Cekic S, Stefanovic V. Ocular melanoma: An overview of the current status. *Int J Clin Exp Pathol*. 2013;6(7):123044.
2. Akpe BA, Omoti AE, Iyasele ET. Histopathology of ocular tumor specimens in Benin City, Nigeria. *J Ophthalmic Vis Res*. 2014;4(4):2327.
3. Mohammed A, Ahmed SA, Ahmedu NE, Maisamari JS. Orbito-ocular malignant tumours in Zaria, Nigeria: A 10-year review. *Ann Afr Med*. 2006;5(3):12931.
4. Taran-Munteanu L, Hartkopf A, Eigentler T, Vogel U, Brucker S, Taran F. A Case of Choroidal Melanoma Metastatic to the Breast. *G e b u r t s h i l f e F r a u e n h e i l k d*. 2016;76(05):57981.
5. Demirci H, Shields CL, Shields JA, Eagle RC, Honavar SG. Bilateral breast metastases from choroidal melanoma. *Am J Ophthalmol*. 2001;131(4):5213.
6. McCormick A, Rennie I, Shields CL, Shields JA. Bilateral breast metastases from choroidal melanoma. *A m J O p h t h a l m o l*. 2001;132(6):9512.
7. Samaraee A Al, Khout H, Barakat T, Fasih T. Breast metastasis from a melanoma. *Ochsner J*. 2012;12(2):14951.
8. Barnett C, Mehta N, Towne WS, Babagbemi K, Sales RM. Metastatic melanoma in the breast and axilla: A case report. *Clin Imaging*. 2022 May 1;85:7882.
9. Pressman PI. Malignant Melanoma and the Breast. *Cancer*. 1973;31(4):7848.
10. Makhubele HD, Mirza MB. Primary Malignant Melanoma of the Breast: Mankweng Breast Oncology Experience. *J Med Res Heal Sci*. 2020;3(3):9003.
11. Bacchi CE, Wludarski SC, Ambaye AB, Lamovec J, Salviato T, Falconieri G. Metastatic melanoma presenting as an isolated breast tumor: A study of 20 cases with emphasis on several primary mimickers. *Arch Pathol Lab Med*. 2013;137(1):419.
12. Ravdel L, Robinson WA, Lewis K, Gonzalez R. Metastatic melanoma in the breast: A report of 27 cases. *J Surg Oncol*. 2006;94(2):1014.
13. Arora R, Robinson WA. Breast metastases from malignant melanoma. *J Surg Oncol*. 1992;50:279.
14. Vinyuvat S. Malignant melanoma presenting as a lump in breast: a case report. *Pathology*. 2014 Jan 1;46:S58.
15. Loffeld A, Marsden JR. Management of melanoma metastasis to the breast: Case series and review of the literature. *Br J Dermatol*. 2005;152(6):120610.
16. Cangiarella J, Symmans WF, Cohen JM, Goldenberg A, Shapiro RL, Waisman J. Malignant melanoma metastatic to the breast. A report of seven cases diagnosed by fine-needle aspiration cytology. *Cancer*. 1998;84(3):1602.