

Original Article

Xanthogranulomatous Pyelonephritis in a Patient with Congenital Anomaly of the Kidney: A Case Report

Olanrewaju TO, Adeyemo AW, Oyedepo DS, Busari KA.

Division of Nephrology, Department of Medicine, University of Ilorin and University of Ilorin Teaching Hospital, Ilorin, Kwara State, Nigeria

Article History

Submitted: 20/11/2022; Accepted: 21/03/2023; Published: 17/4/2023

*Correspondence: olanrewaju.to@umilorin.edu.ng

ABSTRACT

A 69-year-old diabetic woman presented to the medical emergency following a 2-week history of fever and left-sided flank pain, urinary frequency, nocturia and urge-incontinence. No polyuria, and no polydipsia. On examination, she was lethargic, pale, febrile (T038.60C), dehydrated, and marked left-sided renal angle tenderness. Dipstick urinalysis revealed pyuria (3+), ketones (2+), and positive nitrite. Urine microscopy showed numerous white blood cells. Both urine and blood culture yielded significant growth of *Escherichia coli* (extended-spectrum beta-lactamase producer). Abdominopelvic computed tomography and intravenous urogram (CT-IVU) scan showed a mal-rotated and inferiorly-sited left kidney with multiple, rounded hypo-dense lesions with rim enhancement within its parenchyma and right-sided moderate hydronephrosis. A diagnosis of xanthogranulomatous pyelonephritis and diabetic ketoacidosis in an elderly woman with congenital anomaly of the left kidney was made. She was treated with intravenous antibiotics, and counselled for left-sided nephrectomy, but declined surgery. She was followed up in the clinic and had three readmissions before she died four months after the diagnosis.

Keywords: Case report, kidney, pyelonephritis, xanthogranulomatous.

BACKGROUND

Xanthogranulomatous pyelonephritis is a rare destructive granulomatous disorder of kidney parenchyma, which often results from chronic obstruction from renal stones, and less commonly in other forms of urinary tract obstruction. It may be confused with perinephric abscess, renal cell carcinoma and renal tuberculosis because of similar clinical features. We report a case in an elderly diabetic woman with mal-rotated and inferiorly-located left kidney, who has had no previous history of recurrent urinary tract infections, tuberculosis, or stones of the kidney or urinary tract.

CASE PRESENTATION

A 69-year-old woman with diabetes presented to the medical emergency with a 2-week history of high grade, intermittent fever and left-sided flank pain. The flank pain was dull-aching, of moderate intensity and non-radiating. There was no associated flank swelling, haematuria or suprapubic pain. She had urinary frequency, nocturia and urge-incontinence, but no polyuria nor polydipsia. There was associated history of malaise and anorexia but no vomiting, diarrhoea, weight loss or drenching night-sweats. She had no past history of recurrent

Article Access



Website: www.wjmb.com

 10.5281/zenodo.7881424

How to cite this article

Olanrewaju TO, Adeyemo AW, Oyedepo DS, Busari KA. Xanthogranulomatous Pyelonephritis in a Patient with Congenital Anomaly of the Kidney: A Case Report. *West J Med & Biomed Sci.* 2023;4(1-2):7-11. DOI: 10.5281/zenodo.7881424

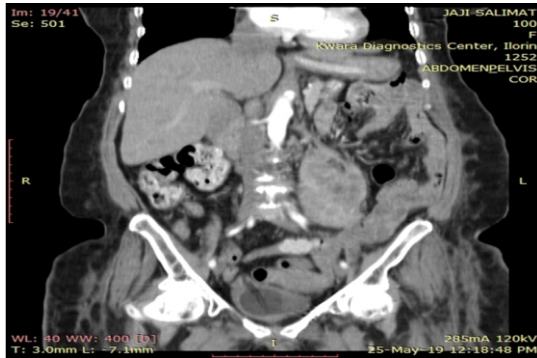


Figure 1: Abdominopelvic computed tomography and intravenous urogram (CT-IVU) scan in patient with xanthogranulomatous pyelonephritis (XGP). It shows multiple hypo-dense lesions in the left kidney illustrating the classic 'bear paw' sign (white arrow).

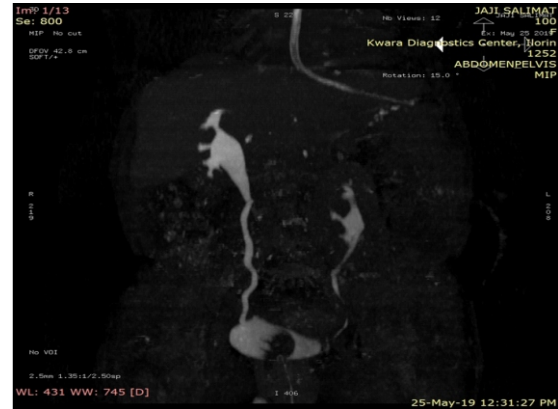

Figure 2: Abdominopelvic computed tomography and intravenous urogram (CT-IVU) scan in patient with xanthogranulomatous pyelonephritis (XGP) on congenital anomaly of left kidney and urinary tract. It shows pelvi-calyceal dilation of right kidney (white arrow) with inferiorly sited and mal-rotated left kidney (blue arrow).

Table 1: Results of the investigations for the patient

| Investigations | Results |
|--|---|
| Random blood sugar | 20.6 (<7.8 mmol/L) |
| Complete blood count | Hemoglobin - 10.7 (12-16g/dL) Packed cell volume – 35 (36-48%) White cell count- 35.6 x10 ⁹ /L (4.0- 10.0 x 10 ⁹ /L) Platelet - 219 x10 ⁹ /L (100,000-450,000 cells/mm ³) Erythrocyte Sedimentation Rate -122 (<20mm/hour) Differential Neutrophil- 92 (45-55%); Lymphocytes-08 (25-40%) Neutrophils showed mild toxic granulations |
| Electrolytes, Urea and Creatinine | Sodium – 127 (135 - 145mmol/L) Potassium - 5.7 (2.9 - 5mmol/L) Chloride- 95 (96 - 106mmol/L) Urea -19.5 (1.7 - 9.2mmol/L) Creatinine - 448 (64 – 124 umol/L) Bicarbonate – 11 (21 - 28mmol/L) Calcium - 2.45 (2.25 - 2.65mmol/L) Phosphate- 1.9 (0.6 - 1.4mmol/L) Albumin - 26 (35 - 50g/L) |
| Urinalysis | Blood - 4+ Ketones -2+ Glucose -3+ Protein -2+ Nitrates -1+ Leucocytes -3+ |
| Urine culture | Yielded significant growth of <i>Escherichia coli</i> (Extended spectrum beta lactamase producer) |
| Urine GeneXpert | Negative |
| Blood culture | Yielded significant growth of <i>Escherichia coli</i> (Extended spectrum beta lactamase producer) |
| HIV Screening | Negative |
| Lipid profile | Total Cholesterol - 9.2 (<5mmol/L) Triglyceride - 2.0 (0.3 – 1.7mmol/L) LDL- 7.9 (0-2.6 mmol/L) HDL-0.5 (>1.20 mmol/L) Atherogenic index- 18.6 (<5.0) |
| Abdominopelvic Computed Tomography and Intravenous Urogram (CT-IVU) scan | Both kidneys showed prompt excretion Left kidney was malrotated and inferiorly sited. It had lobulated outline and measured 10.5 x 5.9cm. Multiple rounded hypodense lesions with rim enhancement were noted within its parenchyma, associated with moderate perinephric fat stranding. Right kidney was noted in its normal position and showed regular outline measuring 11.5 x 5.2cm. There was moderate dilation of pelvicalyceal system. Conclusion was left Xanthogranulomatous pyelonephritis with malrotation. Mild to moderate right hydronephrosis? cause. |

urinary tract infections or kidney and urinary tract stones.

She was a known diabetic of six years with poor drug compliance. She had no history of tuberculosis. The general examination revealed an elderly woman, lethargic, pale, dehydrated, febrile with axillary temperature of 38.6°C, but no significant lymphadenopathy. The vital signs were pulse rate of 110 beats/minute, blood pressure of 140/90mmHg, respiratory rate of 30 cycles/minute with arterial oxygen saturation of 96% in room air. The abdominal examination revealed marked left-sided renal angle tenderness but no palpable mass or organ enlargement.

INVESTIGATION

Table 1 shows the results of the investigations. The random blood sugar at presentation was 20.6 (<7.8 mmol/L). Her urine was purulent, and the dipstick urinalysis revealed haematuria (4+), pyuria (3+), glycosuria (3+), proteinuria (2+), ketonuria (1+) and positive nitrite. Urine microscopy showed numerous white blood cells, 4-6 red blood cells per high-power-field and no casts. Both urine and blood culture yielded significant growth of *Escherichia coli* (extended-spectrum beta-lactamase producer). Urine GeneXpert test was negative for *Mycobacterium tuberculosis*. White cell count was 35.6 (4.0-10.0 x 10⁹/L) with neutrophilia of 92 (45-55%) and toxic granulations on peripheral blood film. Kidney function test revealed azotemia and metabolic acidosis with serum creatinine of 421 (64-124umol/L), urea 22.6 (1.7 - 9.2mmol/L) and bicarbonate of 11 (21 - 28mmol/L). Her erythrocyte sedimentation rate was elevated 122 (<20mm/hour) and retroviral screening was negative. Abdominopelvic computed tomography and intravenous Urogram (CT-IVU) scan, showed a malrotated and inferiorly-sited left kidney with multiple, rounded hypo-dense lesions with rim enhancement within its parenchyma (Figure 1) and right-sided moderate hydronephrosis (Figure 2).

DIAGNOSIS

Acute left-sided xanthogranulomatous pyelonephritis and diabetic ketoacidosis in an elderly woman with

congenital anomaly of the left kidney.

TREATMENT

She was treated with intravenous antibiotics, ceftriaxone initially, and meropenem after sensitivity results came out, intravenous normal saline, and intravenous soluble insulin titrated to serum glucose level till the ketosis subsided. She was placed on continuous bladder drainage via a urethral catheter and multiple bladder irrigations with antibiotic-instilled normal saline. She was counselled on need for left-sided nephrectomy which she declined. She made significant clinical and laboratory improvement and was discharged home after 3-weeks of admission.

Follow up: During the follow-up period, she was readmitted thrice for similar complaints despite long-term antibiotic prophylaxis and bimonthly catheter change. She died after four months of diagnosis.

DISCUSSION

Xanthogranulomatous pyelonephritis (XGP) is a type of chronic pyelonephritis resulting from obstruction in the kidneys and urinary tract majorly caused by renal stones¹. Parsons et al in an analysis of 87 cases between 1958 to 1983 reported an incidence of 1.4 case per 100, 000 Population per annum². Majority were due to obstruction by calculi (75%) while the rest were due to other causes of pelvi-ureteric obstruction². The predominant organisms cultured from the urine of the patients in the study were *Escherichia coli* and *Proteus mirabilis*². A recent 8-year retrospective review of 43 cases of chronic pyelonephritis by Babatunde et al in Kano, reported 5 cases of XGP³. Although all ages and both sexes can be affected, it occurs more frequently in middle aged and older women⁴⁻⁶. Despite the recent review, to the best knowledge of the authors, this is the first reported case of XGP occurring in congenital anomaly of the kidney in Nigeria. The association may result perhaps from obstruction of the urinary tract due to the anomaly of the kidney and urinary tract. XGP results from chronic inflammation in the kidney parenchyma which occurs due to defective clearance of an

invading bacterium by macrophages in an immune-compromised state such as diabetes, and post-organ transplantation. This index case presented with typical features, being an elderly diabetic woman who had not been complying with her medication and thus, also presented with diabetic ketoacidosis. XGP in adults typically presents with fever, flank pain with or without swelling, weight loss and anorexia. In children, there may be fever, abdominal pain and growth retardation¹.

Blood tests may reveal anemia, elevated erythrocyte sedimentation rate, azotaemia, leucocytosis and transaminitis. Urinalysis commonly reveals pyuria and bacteriuria and the cultured organisms are typically *Enterobacteriaceae* such as *Escherichia coli* (as it was found in our patient), *Proteus mirabilis*, and *Enterococcus faecalis*⁶. However, culture may be negative in 25% of cases⁵.

The diagnosis can be made by radiological investigation and confirmed by histo-pathological analysis. Abdominal Computerized tomography scan is the preferred imaging modality which may reveal hypodense areas surrounded by rim enhancement of contrast giving a multi-loculated appearance and corresponds to dilated calyces lined with necrotic tissue extending into the renal parenchyma classically known as “bears paw sign”^{7,8}. Intravenous pyelography can also aid in diagnosis through outlining the urinary tract revealing a non-functional kidney containing multiple stones or sometimes a space occupying lesion indicative of malignancy¹. The diagnosis of XGP in our patient was made based on the typical findings on the contrast-enhanced computed tomography and intravenous Urogram (CT-IVU). The histology of the mass was not done because of the adequacy of information on the CT-IVU. The macroscopic examination of the affected kidneys may reveal necrotic yellowish material surrounded by orange colored tissue as a result of destruction by inflammatory process¹. Renal stones including staghorn calculus can also be found. Microscopic examination essentially consists of three layers centered by a calyx⁹. The inner zone consists of

necrosis, leucocytes, lymphocytes, plasma cells and macrophages while the middle zone contains vascularized granulation tissue interspersed with hemorrhage¹. The inflammatory cells are largely lipid laden macrophages which account for the yellow color and the outermost part of the lesion is characterized by giant cells and cholesterol cleft¹⁰.

Treatment is mainly by surgical resection of affected kidney after treatment with antibiotics to control local infection and prevent septicemia. Total nephrectomy is usually done, but in children, partial nephrectomy can be performed in localized form or in those with bilateral disease¹¹. Our patient declined surgery despite adequate and informed counselling, had multiple re-hospitalizations, and died four months after the diagnosis. This observation calls for education of patients, and the community for a change in attitude and traditional beliefs towards accepting therapeutic surgery.

CONCLUSION

Xanthogranulomatous pyelonephritis is a severe infection of the kidney that requires prompt diagnosis, treatment with antibiotics and nephrectomy in order to obtain a good outcome.

REFERENCES

1. Alain M, Stephen BC, Allyson B. Xanthogranulomatous pyelonephritis. In: UpToDate, Post TW (Ed), UpToDate, Waltham, MA. (Accessed on February 05, 2022)
2. Parsons MA, Harris SC, Longstaff AJ, Grainger RG. Xanthogranulomatous pyelonephritis: a pathological, clinical and aetiological analysis of 87 cases. *Diagn Histo pathol.* 1983;6(3-4): 203-19.
3. Ademola BL, Atanda AT, Aji SA, Abdu A. Clinical, morphologic and histological features of chronic pyelonephritis: An 8-year review. *Niger Postgrad Med J.* 2020 Jan-Mar;27(1):37-41.
4. Chuang CK, Lai MK, Chang PL, Huang MH, Chu SH, Wu CJ et al. Xanthogranulomatous pyelonephritis: experience in 36 cases. *J Urol.* 1992; 147(2): 333-6.

5. Malek RS, Elder JS. Xanthogranulomatous pyelonephritis: a critical analysis of 26 cases of the literature. *J Urol*. 1978; 119(5):589.
6. Goodman M, Curry T, Russel T. Xanthogranulomatous pyelonephritis: a local disease with systemic manifestations. Report of 23 patients and review of literature. *Medicine (Baltimore)*. 1979;58(2): 171-8.
7. Wu ST. Bear paw sign: Classic presentation of xanthogranulomatous pyelonephritis. *QJM*. 2019; 112(6): 461-2.
8. Garrido-Abad P, Rodriguez MA, Vera BR, Platas-Sancho A. Bear paw sign: Xanthogranulomatous pyelonephritis. *J Radiol Case Reo*. 2018; 12(11):18-24.
9. Hill GS Renal Infection. In: *Uropathology*, 1st Ed, Hill GS (Ed), Churchill Livingstone, New York 1989. P333.
10. Zozos I, Moutzouris V, Karakianitis G, Katson G. *Scand J Urol Nephrol*. 2003; 37(4): 342-7.
11. Perez LM, Thrasher JB, Anderson EE. Successful management of bilateral xanthogranulomatous pyelonephritis by bilateral partial nephrectomy. *J Urol*. 1993; 149(1): 100-2.